

# Colon Case Study

onco*type* DX<sup>®</sup>  
*Colon Cancer Assay*

## 74-Year-Old Female Patient

**Tumor Type:** Adenocarcinoma

**Tumor Stage:** Stage III A/B (N1-3)

**Histologic Grade:** Low (1)

**Lymph Node Status:** Positive

**Number of Lymph Nodes Assessed:** 14

**Mismatch Repair (MMR) Status:** MMR-P (MSS)

**Lymphovascular Invasion:** Absent

**Perforation:** Absent

**Obstruction:** Absent

**Other Information:** Patient is in good health, but has blood in stool.

**Treatment:** 5-FU without Oxaliplatin

### CASE SUBMITTED BY:

Fadi Braiteh, MD

Comprehensive Cancer Centers of Nevada  
Las Vegas, NV

# Colon Case Study

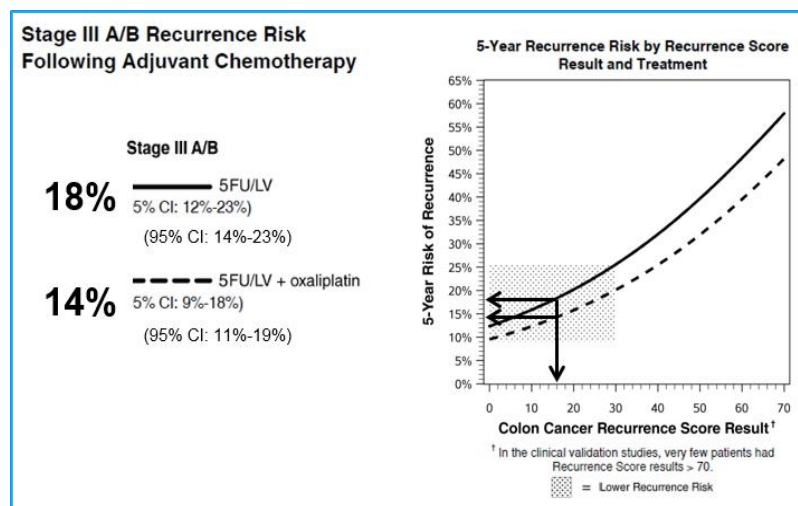
## CLINICAL EXPERIENCE

Recurrence Score = **16**

### Prognosis for Stage III A/B Colon Cancer Patients Following Adjuvant Chemotherapy

The clinical validation study included patients from the NSAPB C-07 trial which randomized 409 stage III A/B patients to 5FU/LV versus 5FU/LV+oxaliplatin.<sup>1</sup>

The average 5 year risk of recurrence for patients who had a Recurrence Score<sup>®</sup> result of 16 was:



Other Considerations: The recurrence risk for patients with  $\geq 12$  nodes examined was lower than the risk for those with  $< 12$  nodes examined.

#### References:

1. Yothers et al. J Clin Oncol. 2013.