

AGE

67

## DCIS BREAST CASE STUDY

PATIENT	67 Year-Old Female Patient
TUMOR SIZE (cm)	4.0
MENOPAUSAL STATUS	Post-Menopausal
ER STATUS (IHC)	ER positive
MULTIFOCAL	N/A
MARGIN WIDTH (mm)	N/A
NUCLEAR GRADE	N/A
COMEDO NECROSIS	N/A
GENERAL HEALTH	Good
OTHER INFORMATION	Treated with radiation
SUBMITTED BY	Gary Unzeitig, MD, Laredo Breast Care, Laredo, TX

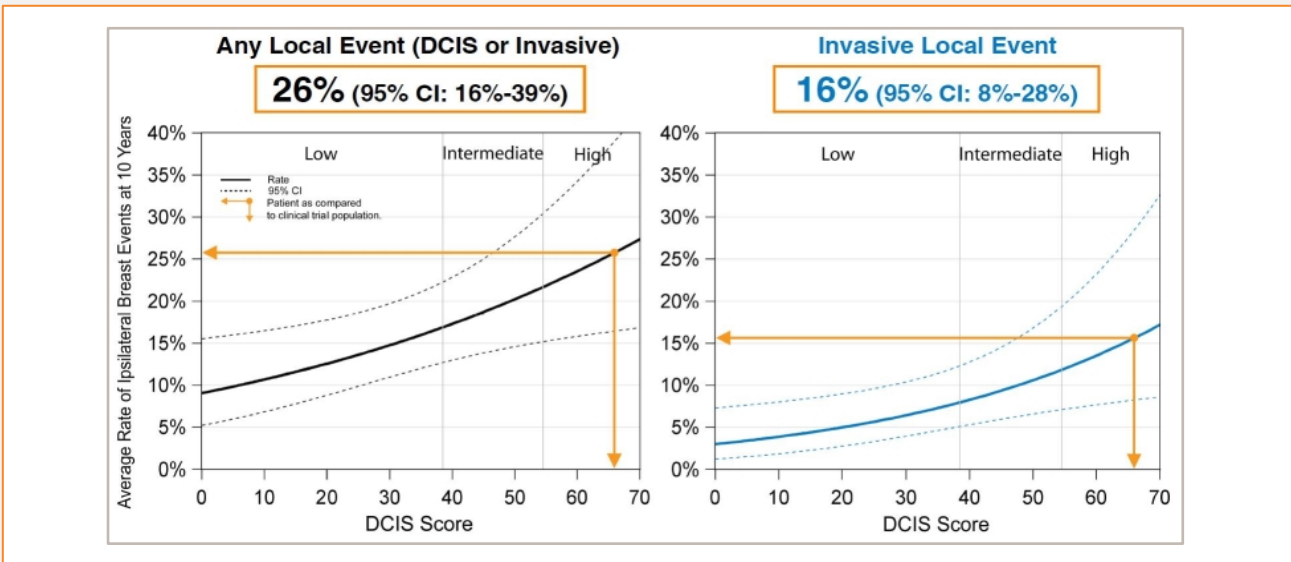
DCIS SCORE™

66

# DCIS BREAST CASE STUDY

## QUANTITATIVE HORMONE RECEPTOR

The Clinical Validation study<sup>1</sup> included female patients with DCIS treated with local excision without irradiation, and required clear surgical margins  $\geq 3$  mm and a lesion size of  $\leq 2.5$  cm. Approximately a third of patients were treated with tamoxifen. The average 10 year rate for ipsilateral breast events for patients who had a DCIS Score of 66 was:



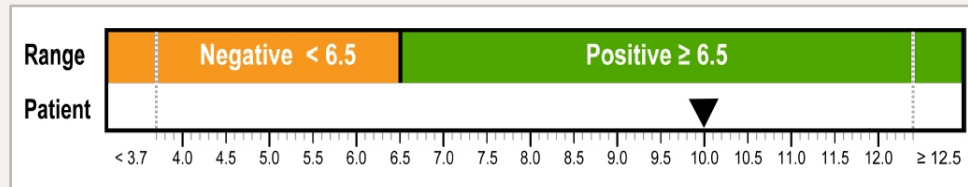
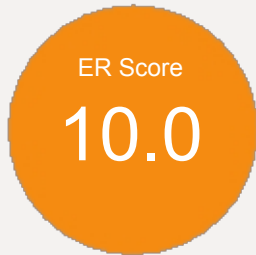TREATMENT GIVEN

N/A

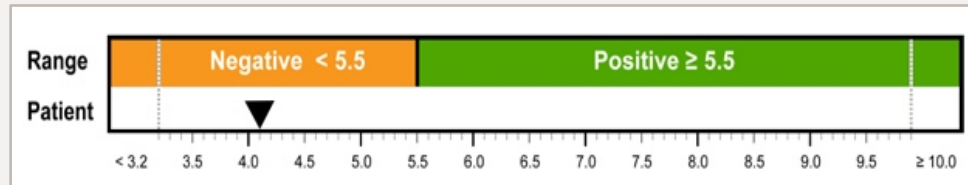
# DCIS BREAST CASE STUDY

## CLINICAL INFORMATION

The Oncotype DX test uses RT-PCR to determine the RNA expression of the genes below. These results may differ from ER or PR results reported using other methods or reported by other laboratories.



N/A



N/A

### References

1. Solin et al. J Natl Cancer Inst. 2013.
2. ER Score based on quantitative ESR1 expression (estrogen receptor); PR Score based on quantitative PGR expression (progesterone receptor).
3. Badve et al. J Clin Oncol. 2008. May 20;25(15):2473-81
4. Paik et al. ASCO 2005.