

# Colon Case Study

onco*type* DX<sup>®</sup>  
*Colon Cancer Assay*

## 67-Year-Old Female Patient

**Tumor Type:** Adenocarcinoma

**Tumor Stage:** Stage III A/B (N1-3)

**Histologic Grade:** Low (1)

**Lymph Node Status:** Positive

**Number of Lymph Nodes Assessed:** 15

**Mismatch Repair (MMR) Status:** MMR-P (MSS)

**Lymphovascular Invasion:** Absent

**Perforation:** Absent

**Obstruction:** Absent

**Other Information:** Patient has hypertension, P.E

**Treatment:** Capecitabine (Xeloda) and Oxaliplatin

### CASE SUBMITTED BY:

Putao Cen, MD

University of Texas

Houston, TX

# Colon Case Study

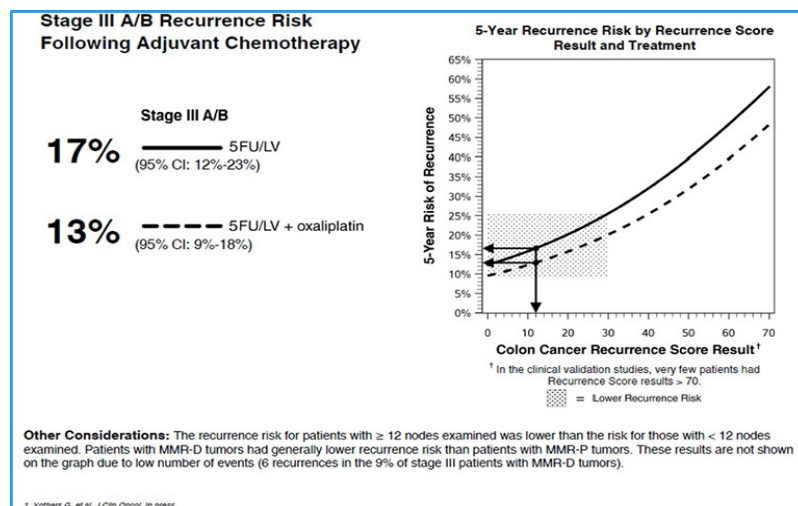
## CLINICAL EXPERIENCE

Recurrence Score = **13**

### Prognosis for Stage III A/B Colon Cancer Patients Following Adjuvant Chemotherapy

The clinical validation study included patients from the NSAPB C-07 trial which randomized 409 stage III A/B patients to 5FU/LV versus 5FU/LV+oxaliplatin.<sup>1</sup>

The average 5 year risk of recurrence for patients who had a Recurrence Score® result of 13 was:



Other Considerations: The recurrence risk for patients with ≥ 12 nodes examined was lower than the risk for those with < 12 nodes examined.

#### References:

1. Yothers et al. J Clin Oncol. 2013.